

Special Section on Bile Acids, Drug Metabolism, and Toxicity—Minireview

Strategies to Diagnose Nonalcoholic Steatohepatitis: A Novel Approach to Take Advantage of Pharmacokinetic Alterations

Solène Marie¹, David K.K. Tripp¹, and Nathan J. Cherrington

Department of Pharmacology and Toxicology, College of Pharmacy, University of Arizona, Tucson, Arizona

Received February 10, 2021; accepted September 13, 2021

ABSTRACT

Nonalcoholic steatohepatitis (NASH) is the progressive form of nonalcoholic fatty liver disease (NAFLD) and is diagnosed by a liver biopsy. Because of the invasiveness of a biopsy, the majority of patients with NASH are undiagnosed. Additionally, the prevalence of NAFLD and NASH creates the need for a simple screening method to differentiate patients with NAFLD versus NASH. Noninvasive strategies for diagnosing NAFLD versus NASH have been developed, typically relying on imaging techniques and endogenous biomarker panels. However, each technique has limitations, and none can accurately predict the associated functional impairment of drug metabolism and disposition. The function of several drug-metabolizing enzymes and drug transporters has been described in NASH that impacts drug pharmacokinetics. The aim of this review is to give an overview of the existing noninvasive strategies to diagnose NASH and to propose a novel strategy based on altered pharmacokinetics using an exogenous

biomarker whose disposition and elimination pathways are directly impacted by disease progression. Altered disposition of safe and relatively inert exogenous compounds may provide the sensitivity and specificity needed to differentiate patients with NAFLD and NASH to facilitate a direct indication of hepatic impairment on drug metabolism and prevent subsequent adverse drug reactions.

SIGNIFICANCE STATEMENT

This review provides an overview of the main noninvasive techniques (imaging and panels of biomarkers) used to diagnose NAFLD and NASH along with a biopsy. Pharmacokinetic changes have been identified in NASH, and this review proposes a new approach to predict NASH and the related risk of adverse drug reactions based on the assessment of drug elimination disruption using exogenous biomarkers.

Introduction

Nonalcoholic fatty liver disease (NAFLD) is a broad range of chronic liver diseases characterized by the accumulation of fat in the liver called steatosis, which is not related to the consumption of alcohol (Chalasani et al., 2018). NAFLD may develop into its progressive form, nonalcoholic steatohepatitis (NASH), which is accompanied by inflammation and hepatocyte ballooning, with risk for fibrosis (Ahmed et al., 2015). Notably, NASH is considered the second most common indication for liver transplant in patients with chronic liver diseases (Goldberg et al., 2017; Younossi et al., 2021). The progression to NASH from simple NAFLD increases the risk of comorbidities, such as cardiovascular

disorders, metabolic diseases, and complications, including cirrhosis and hepatocellular carcinoma (Singh et al., 2015; Adams et al., 2017). Therefore, the ability to screen for NAFLD accurately and safely and, more specifically, NASH is crucial to public health.

An epidemiologic meta-analysis estimated the global prevalence of NAFLD at 25.24% (Younossi et al., 2016). The analysis suggested significant geographic disparities with highest prevalence of NAFLD in the Middle East and South America (31.79% and 30.45%, respectively) and lowest in Africa (13.48%) (Younossi et al., 2016). This study also illustrated disparities related to the diagnostic methods: only the studies using imaging to diagnose NAFLD were included in the calculation of the prevalence because of their better accuracy (Younossi et al., 2016). However, the pooled regional NAFLD prevalence was drastically lower when calculated based on blood test diagnosis than on imaging (for example 12.89% with blood test vs. 24.13% with imaging in North America) (Younossi et al., 2016). These results suggest an underestimation using blood tests in diagnosing NAFLD, probably due to fluctuating liver enzymes in the disease (Younossi et al., 2016). Among biopsied patients

This work was supported by National Institutes of Health National Institute of Environmental Health Sciences [Grants ES028668 and ES006694].

¹S.M. and D.K.K.T. contributed equally to this work.

dx.doi.org/10.1124/dmd.121.000413.

ABBREVIATIONS: ADR, adverse drug reaction; ALT, alanine transaminase; APAP, acetaminophen; AST, aspartate transaminase; BCRP, breast cancer resistance protein; BMI, body mass index; CAP, controlled attenuation parameter; CT, computed tomography; EASL, European Association for the Study of the Liver; FLI, Fatty Liver Index; GGT, γ -glutamyl transferase; HSI, Hepatic Steatosis Index; HU, Hounsfield unit; LAP, Lipid Accumulation Product; miRNA, microRNA; MR, magnetic resonance; MRE, magnetic resonance elastography; MRP, multidrug resistance-associated protein; NAFLD, nonalcoholic fatty liver disease; NASH, nonalcoholic steatohepatitis; NFS, NAFLD fibrosis score; NTCP, sodium taurocholate protein; OAT, organic anion transporter; OATP, organic anion-transporting polypeptide; PDFF, proton density fat fraction; P-gp, P-glycoprotein; P NP LA, patatin-like phospholipase domain-containing protein-; SULT, sulfotransferase; US, ultrasound; VCTE, Vibration-Controlled Transient Elastography; WC, waist circumference.

with NAFLD, the analysis showed the prevalence of NASH was 59.10% (Younossi et al., 2016). However, the overall prevalence of NASH in the general population is actually estimated at only 1.5%–6.45%, probably because diagnosis requires histologic confirmation by biopsy (Younossi, 2018).

Liver biopsy is considered the “gold standard” to diagnose NAFLD and to assess its progression to NASH (Younossi et al., 2018a). The NAFLD activity score is a commonly proposed method to measure disease progression consisting of a compilation of unweighted factors calculated from biopsy (steatosis, lobular inflammation, and hepatocyte ballooning), with their sum indicating the degree of NAFLD (Kleiner et al., 2005). The sum ranges from 0 to 8, and a result ≥ 5 indicates NASH, whereas a score ≤ 2 is described as “no-NASH” (Brunt et al., 2011). Although liver biopsy is the “gold standard” for diagnosing NAFLD and NASH, this technique is not always consistent because of interoperator and intraoperator errors that can occur in both biopsy sampling and NAFLD activity scoring (Bedossa, 2014). Because of the invasiveness of the procedure, there is a risk of pain, bleeding, and infection (Rockey et al., 2009; Arab et al., 2018; Chalasani et al., 2018). Performing a biopsy without other strong indication of disease progression or future complications can be excessive in most patients, especially considering the lack of approved treatments for NAFLD and NASH (Younossi et al., 2018b).

In the United States, systematic screening of NAFLD is not recommended because the gray area between NASH and “no-NASH” of early-onset disease is difficult to assess unless indicators suggest advanced fibrosis (Chalasani et al., 2018). However, some studies indicate that patients with NAFLD may have an increased risk for adverse drug reactions (ADRs), including drugs largely used in the general population, such as acetaminophen, corticosteroids, antibiotic, or antidiabetic drugs (Chalasani et al., 2015; Massart et al., 2017; Allard et al., 2019; Lammert et al., 2019). Identifying these patients with NAFLD and NASH at risk of ADRs may be valuable to propose personalized treatments and limit ADR onset and their consequences on health. Thus, other modes of diagnosing NAFLD are often explored prior to biopsy, avoiding this invasive procedure when possible and relying mostly on blood tests, risk factors, and imaging modalities (Younossi et al., 2018a). Although these techniques are accurate to detect steatosis and fibrosis, no individual test has an accuracy comparable to biopsy to draw a distinction between NAFLD and the nonfibrotic early stage of NASH, nor do they offer any information regarding the increased risk for ADRs (Chalasani et al., 2018). Consequently, there is a need for more accurate, noninvasive tests to diagnose NASH at its earliest onset and for a direct functional assessment of liver impairment that may indicate an increased risk of ADR due to altered drug metabolism and transport capacity. The ability to predict NASH and the related risk of ADRs

would be a powerful tool in the hands of clinicians tracking disease progression in patients. Herein is an overview of the current noninvasive methods used for diagnosing NASH as well as a proposed novel strategy to predict disease stage based on drug disposition.

Imaging Diagnosis

Noninvasive imaging techniques have been developed to make NASH diagnosis simpler and safer to apply than biopsy and offer an advantage for patients and clinicians (Madrado, 2017). Imaging techniques enable a complete surveillance of the liver, which is valuable when the distribution of fat or other pathologic features in a liver are not uniform. In these cases, a biopsy-based diagnostic can fail if the sample is not collected in the damaged part of the liver, whereas imaging techniques offer a more global overview of the liver (Sumida et al., 2014).

Imaging NAFLD. The first and most common method developed for the diagnosis of NAFLD is ultrasound (US), in which the appearance of hepatomegaly with hyperechogenic hepatic tissues (showing more echogenicity than the kidneys), vascular blurring, and deep attenuation on ultrasonography are consistent with liver steatosis (Table 1) (Obika and Noguchi, 2012; Madrado, 2017). Steatosis is reported to be detectable by US when more than 20% of hepatocytes contain histologically visible fat (Shannon et al., 2011). However, the accuracy of US in detecting hepatic steatosis is affected by the presence of severe fibrosis, morbid obesity, or in individuals with mild steatosis with a fatty change of less than 23%–30% (Sumida et al., 2014; Zhou et al., 2019). Recently, researchers have tried to improve this technique by developing US adaptive sound speed as a score of steatosis (Imbault et al., 2017, 2018; Dioguardi Burgio et al., 2019). Although this procedure is associated with significant interobserver and intraobserver variability and is operator-dependent, it remains the first-line imaging test used in clinical practice especially for screening of suspected NAFLD because of its lack of invasiveness, wide availability, and relatively low cost (Singh et al., 2013; European Association for the Study of the Liver (EASL) et al., 2016).

Liver imaging by computed tomography (CT) is available to assess steatosis by measuring the attenuation that is correlated with the degree of intrahepatic fat accumulation (Table 1) (Li et al., 2018b). Hepatic attenuation is inversely associated with the fat content, which means that a fatty liver has a lower attenuation on CT images than a normal liver (Lee and Park, 2014). The most common CT method of diagnosing NAFLD involves the determination of liver attenuation of scans compared with that of the spleen (the liver-to-spleen attenuation difference). Normal liver has an attenuation value of 50–65 Hounsfield units (HU), which is generally 8–10 HU higher than that of the spleen (Li et al., 2018b). In contrast, the attenuation value of the liver may decrease to less than 40 HU when fatty infiltration occurs, and a lower hepatic

TABLE 1
Overview of the main imaging techniques used for diagnosing NAFLD and NASH

Approaches	Applications	Limitations
CAP	Stiffness and steatosis simultaneously measured based on VCTE.	High rates of missed or wrong diagnosis in the patients with a high stage of steatosis and obesity.
CT	Steatosis by measurement of attenuation, which is correlated with the degree of intrahepatic fat accumulation.	Radiations.
MR	Steatosis by signal intensity differences on opposed-phase or fat saturation.	Price and equipment.
MR-PDFF	Steatosis by dividing all protons in the liver using MRI-visible protons bound to fat.	Price and equipment.
MRE	Stiffness based on shear wave propagation using MR modality.	Price and equipment.
US	Steatosis based on appearance of hepatomegaly with hyperechogenic hepatic tissues, vascular blurring, and deep attenuation.	Accuracy may be affected by the presence of severe fibrosis or morbid obesity or in individuals with mild steatosis.
VCTE	Stiffness by quantifying the speed of shear wave emitted by a vibrator in the intercostal space and followed by US.	Detection limited to a local scale of the tissue.

attenuation of 10 HU relative to the spleen is consistent with hepatic steatosis (Madrazo, 2017). Nonenhanced CT is more commonly used than enhanced CT and outperforms US in evaluating the severity of steatosis, achieving a specificity of 100% and sensitivity of 82% for diagnosing higher degrees of hepatic steatosis (>30%) (Park et al., 2006). Nevertheless, the inconvenience of CT is that this method is associated with the use of radiation involving larger doses than the more common conventional X-ray imaging procedures and is considered a carcinogenic risk (Brenner and Hall, 2007). For these reasons, CT is not routinely used to screen for NAFLD in clinical practice.

The more recent introduction of magnetic resonance (MR) expanded the ability to diagnose NAFLD via imaging. MR determines steatosis by signal intensity differences on opposed-phase or fat saturation (Table 1) (Springer et al., 2010). The sensitivity and specificity of MR for detecting histologically confirmed steatosis ($\geq 5\%$) are both approximately 90% (Li et al., 2018b). Several MR sequences have been developed to biochemically assess the liver, such as MR spectroscopy, opposed-phase imaging, or complex-based chemical shift imaging-based MR (Madrazo, 2017; Zhou et al., 2019). An advanced and robust technique for assessing hepatic steatosis is MR-derived proton density fat fraction (PDFF; Table 1) (Dulai et al., 2016). It enables the determination of the liver fat fraction using MRI-visible protons bound to fat in the liver to quantify steatosis by dividing all protons in the liver. Thus, the liver signal on MRI is split into water and fat signal components by measuring gradient echoes at appropriately spaced echo times to quantify the percentage of liver fat (Yokoo et al., 2011). A robust correlation was reported between the results with PDFF and histologic assessment of steatosis with higher performances for PDFF, with no impact of obesity on the results (Tang et al., 2013; Zhou et al., 2019). PDFF has been shown the most accurate imaging method for measuring hepatic fat content and is even more sensitive than the histology-determined steatosis grade in quantifying longitudinal changes (Noureddin et al., 2013). It allows fat mapping of the entire liver and can be determined with any clinical MR platform so it can easily be used as an imaging biomarker to quantify changes in liver fat. Compared with CT, PDFF offers the advantage to be a nonradiative modality allowing for a follow-up of the disease over the time with promising sensitivity to assess longitudinal changes.

However, the applications of these imaging methods are still relatively limited in the detection of inflammation, which is more important than steatosis in terms of its high risk for fibrosis, cirrhosis, and hepatocellular carcinoma (Li et al., 2018b). It is also difficult to distinguish NAFLD from NASH with these routine imaging techniques because NASH consists of various parameters, including liver fibrosis, which can cause progressive liver damage, and none of these techniques can predict the degree of liver fibrosis (Zhou et al., 2019).

Imaging NASH. Elastography is a method developed more recently that can help to distinguish NASH from simple steatosis. It consists of measuring the degree of tissue stiffness by quantifying the speed of propagation of a shear wave through tissue (Madrazo, 2017). Scales for grading tissue stiffness have been compared with the degree of fibrosis seen on biopsies of the liver (Deffieux et al., 2015). This technique allows the presence of fibrosis in tissues to be predicted by the degree of stiffness, which is often a sign of steatohepatitis present in NASH and not yet in NAFLD. Elastography can be performed both by US and MR (Zhou et al., 2019).

The first Food and Drug Administration–approved and widely used elastography method is the Vibration-Controlled Transient Elastography (VCTE; Fibroscan, Echosens) employing US (Table 1) (Sandrin et al., 2002; Wong et al., 2010). This technology assesses hepatic stiffness by quantifying the speed of shear wave emitted by a vibrator in the intercostal space and followed by US (Li et al., 2018b). When hepatic tissue has fibrous elements, the US transmission wave is faster than in normal

tissues, and the velocity is positively related to liver stiffness (Zhou et al., 2019). VCTE is largely used because of its exceptional quantification capacity, but the detection is limited to a local scale of the tissue. A more recent approach based on VCTE, controlled attenuation parameter (CAP), simultaneously measures stiffness and steatosis (Table 1) (Myers et al., 2012). Even though the CAP method has been considered a promising noninvasive test for diagnosing and staging of hepatic steatosis, a recent systematic review reported the limits of this technique, such as the high rates of missed or wrong diagnosis in patients with a high stage of steatosis and obesity (Pu et al., 2019). This limitation restricts its application, especially when patients present with metabolic syndrome, which is often the case for this diagnostic. MR elastography (MRE) is also based on shear wave propagation but with MR modality, using a modified phase-contrast sequence and an external mechanical actuator to induce and noninvasively visualize propagating tissue shear waves (Table 1) (Cui et al., 2015; Doycheva et al., 2016; Li et al., 2018b). MRE offers the advantage to perform 3-dimensional imaging and to assess the entire liver with a high success rate. It is not affected by steatosis and may be applied in patients with obesity, ascites, or intestinal interposition between the liver and anterior abdominal wall (Yin et al., 2007; Venkatesh et al., 2013). However, MRE is expensive and requires heavy equipment, which makes it difficult for wide applications. More competitive, feasible, and easy to implement methods are needed for diagnosing NASH, especially for initial NASH without fibrosis.

Biomarkers and Panels

Assessing NAFLD. Although NAFLD is occasionally identified incidentally by imaging, elevated aminotransferase levels are the first indication of hepatic impairment for most patients. However, liver enzymes alone are neither sufficient nor reliable to diagnose NAFLD. A study suggested that up to 80% of patients with NAFLD may present normal levels of alanine transaminases (ALTs) (Browning et al., 2004). Thus, several panels of biomarkers have been developed, striving to detect hepatic steatosis and to guide further investigations by way of liver biopsy or imaging (Piazzolla and Mangia, 2020).

Among the scoring systems and panels of biomarkers that have been well validated, the Fatty Liver Index (FLI) has been demonstrated as a simple and accurate predictor of NAFLD (Table 2) (Bedogni et al., 2010). The FLI uses easy-to-obtain parameters, such as body mass index (BMI), waist circumference (WC), serum levels of triglycerides, and γ -glutamyl-transferase (GGT). FLI has shown good performance in detecting fatty liver but a poor ability to distinguish moderate-to-severe steatosis from mild steatosis (Fedchuk et al., 2014). A simplified index adjacent to the FLI is the Lipid Accumulation Product (LAP), which relies only on the measurement of WC and the serum level of triglycerides weighted by sex (Table 2). This index was first developed to identify cardiometabolic disorders but has been shown to be a simple and reasonably accurate predictor of steatosis (Bedogni et al., 2010). Both FLI and LAP have been developed in Caucasian populations but demonstrated difficulties in other populations because of differences in BMI and WC. For this reason, Lee et al. (2010) developed the Hepatic Steatosis Index (HSI), which was assessed in a large cohort of Korean patients (Table 2). This index is calculated based on aspartate transaminase (AST) and ALT ratio, BMI, sex information, and type 2 diabetes with a good prediction for NAFLD (Lee et al., 2010). Nevertheless, the HSI accuracy decreases in children who are obese, and similarly to the FLI, the HSI poorly distinguishes moderate-to-severe steatosis from mild steatosis (Fedchuk et al., 2014).

Interestingly, although the above-mentioned scores were validated against US imaging for steatosis, the NAFLD Liver Fat Score (NLFS) was standardized against MR spectroscopy. This score includes as variables the fasting serum insulin and AST levels, the AST/ALT ratio, and

TABLE 2
Overview of the main panels of biomarkers used for diagnosing NAFLD and NASH and the parameters involved in each panel

Panel	Applications	α 2-Macroglobulin	Albumin	Apolipoprotein A1	Age	ALT	AST	AST/ALT ratio	Bilirubin	BMI	Cholesterol	Sex	GGT	Glucose	Glutamate	Glycine	Haptoglobin	Height	Hyaluronic acid	Hypertension	Insulin	Isoleucine	Lysophosphatidylcholine 16:0	Metabolic syndrome	Phosphoethanolamine 40:6	Platelet count	PNPLA3 genotype	Type 2 diabetes	Triglycerides	Waist circumference	Weight		
BARD score	Fibrosis																																
Fib-4	Fibrosis																																
FLI	Steatosis																																
HAIR score	NASH																																
HSI	Steatosis																																
LAP	Steatosis																																
NFS	Fibrosis																																
NASH ClinLipMet score	NASH																																
NASHTest	NASH																																
NLFS	Steatosis																																
Palekar score	NASH																																
SteatoTest	Steatosis																																

BARD, BMI, AST/ALT ratio, and the presence of type 2 diabetes; HAIR, hypertension, ALT, and insulin resistance; NLFS, NAFLD Liver Fat Score.

the presence of metabolic syndrome and type 2 diabetes (Table 2). However, the inclusion in the formula of serum insulin level, which is not a routine test, is a limitation to its wide clinical use (Piazzolla and Mangia, 2020). Another test validated with liver biopsy as reference is the commercial biomarker panel SteatoTest (Biopredictive, Paris, France). It uses the combination of several biochemical parameters (serum levels of total cholesterol, triglycerides, glucose, bilirubin, GGT, α 2-macroglobulin, haptoglobin, apolipoprotein A1, and ALT) associated to age, sex, and BMI (Table 2) (Poynard et al., 2005). The accuracy of this test is limited by the potential variability of BMI and total bilirubin, which is why a second version of this test has recently been developed, excluding these two parameters (Poynard et al., 2019).

Given the lack of evidence for cost-effectiveness of systematic screening for NAFLD, the American Association for the Study of Liver Disease does not currently recommend it unless there is a suspicion of advanced fibrosis (Chalalani et al., 2018). EASL, however, has advised its screening in patients with obesity, type 2 diabetes, or metabolic syndrome (European Association for the Study of the Liver (EASL) et al., 2016). Although these scores have potential in predicting NAFLD, they will most likely serve as indicators in the early screening steps to detect hepatic steatosis risk in patients. Nevertheless, these tools are valuable in assessing NAFLD to predict NASH at an early stage alongside other biomarkers used for inflammation and fibrosis diagnosis.

Assessing NASH. Although screening for NAFLD is a major element to identify patients with NASH, there is a gap between noninvasive prediction of NAFLD and NASH. No test currently distinguishes patients with NAFLD from patients with NASH in clinical settings beside liver biopsy. However, several steps have been made toward creating predictors of NASH that have utility in helping to identify which patients need a biopsy. NASH is a progressive form of NAFLD in which the steatosis is often associated with inflammation, fibrosis, and hepatocyte ballooning or other hepatocellular injury. Several biomarkers and biomarker panels associated with these features have been studied as predictors of the disease. A few of the major biomarkers are discussed here.

One of the most studied biomarkers for NASH is cytokerin-18 fragment levels, a marker of hepatocyte apoptosis cleaved during the period of cell death (Wieckowska et al., 2006). This biomarker has been considered promising in NASH diagnosis, but some issues were identified later, such as limited sensitivity at the individual level and considerable variability in the suggested cutoffs and their respective diagnostic accuracy (Castera et al., 2019). Other individual biomarkers explored are inflammatory markers, such as tumor necrosis factor- α and interleukin 8, but also showed moderate performances with variability across studies (Qi et al., 2017). Other biomarkers to assess fibrosis and collagen levels, particularly procollagen III, which reflects the expression of extracellular matrix turnover, have been explored (Tanwar et al., 2013).

However, each biomarker considered individually for the diagnosis of NASH has been inadequate given the complexity of the disease. To improve performance, a variety of multiple predictive panels have been developed over the last two decades, combining several biomarkers assessing different features of the disease to offer a general overview of disease stage. One of the first panels is the HAIR score, named according to the parameters included in the panel: hypertension, ALT, and insulin resistance (Table 2) (Dixon et al., 2001). Later, Palekar et al. (2006) generated a panel of six markers combining age, sex, AST, BMI, AST/ALT ratio, and serum hyaluronic acid (Table 2). The NASHTest (Biopredictive, Paris, France) combines 13 parameters (age, sex, height, weight, serum levels of triglycerides, cholesterol, α 2-macroglobulin, apolipoprotein A1, haptoglobin, GGT, ALT, AST, and total bilirubin; Table 2) and enables a classification of the disease in three categories called NASH, borderline NASH, and no-NASH (Poynard et al., 2006). More recently, the new NASH ClinLipMet score was developed, derived from a

previous panel, the NASH Clin score, but improved by adding metabolic syndrome-based factors (Zhou et al., 2016). The originality of this panel is to combine genetic, clinical, lipidomic, and metabolomic markers (glutamate, isoleucine, glycine, lysophosphatidylcholine 16:0, phosphoethanolamine 40:6, AST, fasting insulin, and patatin-like phospholipase domain-containing protein PNPLA3 genotype) (Table 2). However, this panel is not widely used because of the measurements of fasting insulin and PNPLA3, which are complex and costly (Zhou et al., 2019). These scores are predictive of the disease with a sensitivity generally around 80% in the tested cohorts, but none are able to precisely differentiate NASH from simple NAFLD (Obika and Noguchi, 2012). Combination of these panels with others assessing fibrosis (the most clinically relevant factor for disease outcomes) can improve diagnostic accuracy. Several panels have initially been developed for the clinical diagnosis of hepatitis but can be adapted to NASH. Among them, a simple test is the Fib-4 test, which includes age, platelet count, AST, and ALT (Table 2) (Vallet-Pichard et al., 2007). Shah et al. (2009) validated its use in patients with NAFLD in a study demonstrating its superiority to seven other panels of fibrosis biomarkers. The study involved some easy panels widely used in clinical practice, such as the BARD score containing the parameters of BMI, AST/ALT ratio, and the presence of type 2 diabetes or the NAFLD fibrosis score (NFS) consisting of age, BMI, hyperglycemia, AST/ALT ratio, platelets, and albumin (Table 2) (Angulo et al., 2007; Ruffillo et al., 2011). Both American and European guidelines recommend the use of Fib-4 and NFS to identify patients with NAFLD at risk for fibrosis (European Association for the Study of the Liver (EASL) et al., 2016).

Beyond these well known and validated panels of biomarkers, a variety of novel blood-based biomarkers are actually emerging, as detected in circulating extracellular vesicles (Piazzolla and Mangia, 2020). Recent studies showed that the release of some ectosomes and exosomes is increased in patients with NAFLD and NASH and that the molecules transported in these vesicles could be used to detect the disease (Kornek et al., 2012; Chen et al., 2018; Malhi, 2019). Different proteins may be of interest, such as the CD10 protein, whose increase in urinary exosomes was associated with steatosis and fibrosis in transgenic mice, with a change detected at the early stage of the disease and consistent over the time of the progression (Conde-Vancells et al., 2010). Other promising biomarkers are small noncoding microRNA (miRNA) that transcriptionally regulate gene expression (Newman et al., 2020). Diverse *in vitro* and *in vivo* studies reported upregulation of miRNA observed in NAFLD and NASH

(Lee et al., 2005; Pirola et al., 2015). The most relevant of them is the miRNA-122, which is involved in lipid metabolism and whose serum concentrations have been shown upregulated in NASH, whereas the hepatic concentrations were downregulated, probably due to an increase of the release (Szabo and Csak, 2016).

Altered Drug Elimination as a Predictor of NASH

A major concern for patients with chronic liver diseases is the impairment of liver function and consequently the related risk of drug elimination disruption. The imaging techniques and biomarker panels discussed thus far assess different features of NAFLD and NASH diseases but do not provide information about the impairment of the pharmacokinetic process. Noninvasively predicting the risk of drug toxicity associated with these liver impairments has been elusive so far and would be an imperative predictive tool for patients. Because the liver plays a key role in the metabolism and disposition of numerous drugs, a novel strategy to distinguish patients with NASH from NAFLD could be developed to exploit alterations in the function of drug-metabolizing enzymes and transporters that are specific to NASH. Here, we offer our perspective regarding the opportunities and challenges of this new and noninvasive method that could be used to easily assess disease progression as well as a direct indication of hepatic impairment to reduce the risk of ADRs.

The liver plays a central role in the pharmacokinetics of drugs. Drug-metabolizing enzymes and transporters provide the underlying absorption, distribution, metabolism, and elimination mechanisms, and NASH has been shown to cause disease-specific alterations to the function of numerous enzymes and transporters (Li et al., 2018a). Several of these metabolic pathways have been largely characterized, and changes in elimination could be used as a predictive tool so long as the mechanistic alterations in enzyme and transporter functions are specific to the progression to NASH.

Many phase I biotransformation enzymes were analyzed for mRNA, protein, and enzymatic activity in patients with varying progression of NAFLD to NASH (Fisher et al., 2009). The main changes identified were a decrease in cytochromes CYP1A2 and CYP2C19 mRNA, protein levels, and enzymatic activities, whereas they were increased for CYP2C9 and CYP2A6 (Fig. 1). Another study conducted in pediatric patients confirmed a significant reduction in CYP2C19 activity, which appears to be the cytochrome most highly impacted by NASH (Li et al., 2017). A decrease in CYP3A4 mRNA expression and CYP3A activity has also been reported

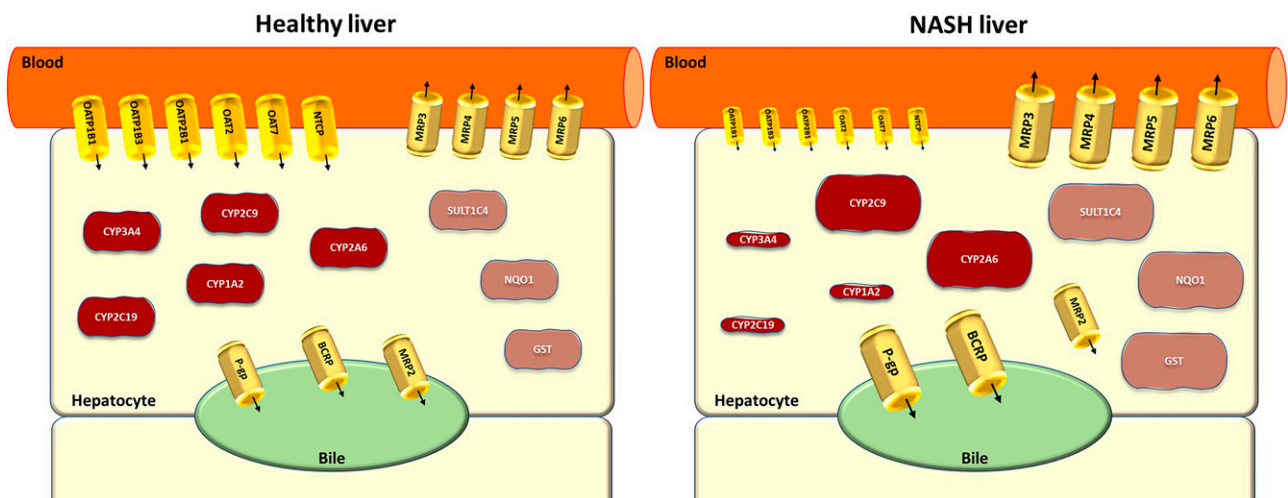


Fig. 1. Main pharmacokinetic changes reported in NASH compared with a healthy liver. The activity of the influx transporters (OATP1B1, OATP1B3, OATP2B1, OAT2, OAT7, NTCP) is decreased, whereas the activity of the efflux transporters (BCRP, P-gp, MRP3, MRP4, MRP5, MRP6) is increased, with a mislocalization of MRP2. The activity of the phase I metabolism enzymes is both decreased (CYP1A2, CYP2C19, CYP3A4) and increased (CYP2C9, CYP2A6), whereas some of the phase II metabolism enzymes (SULT1C4, NAD(P)H:quinone oxidoreductase 1 (NQO1), glutathione S-transferase (GST)) present an increase of the activity.

in patients with NAFLD (Woolsey et al., 2015) (Fig. 1). Enzymes responsible for phase II biotransformation showed that sulfotransferase (SULT) IC4 increased in mRNA and protein expression in NASH (Hardwick et al., 2013) (Fig. 1). Additionally, other enzymes involved in the antioxidant response may also be impacted by NASH, such as the NAD(P)H:quinone oxidoreductase 1 and glutathion transferases whose mRNA, protein expressions, and activity are increased in patients with NASH (Hardwick et al., 2010) (Fig. 1).

Regarding transporters, most of the hepatic ATP-binding cassette family have been reported to have increased protein expression levels in patients with NASH (Hardwick et al., 2011; Tanaka et al., 2012; Okushin et al., 2016). These proteins are involved in the efflux of substrates from the liver into bile [e.g., P-glycoprotein (P-gp) and the breast cancer resistance protein (BCRP)] mediating biliary efflux at the canalicular membrane or from the liver into blood [multidrug resistance-associated protein (MRP) 1, MRP3, MRP4, MRP5, MRP6] responsible for sinusoidal efflux (Fig. 1). Interestingly, the canalicular transporter MRP2 was described to have an altered localization, resulting in a loss of its efflux activity (Canet et al., 2015) (Fig. 1). Contrary to the ATP-binding cassette family transporters, the majority of uptake transporters of the Solute Carrier family expressed in the liver have been shown to have decreased protein expression levels in patients with NASH (Vildhede et al., 2020). These transporters are localized on the sinusoidal membrane where they mediate the hepatic uptake of substrates (Fig. 1). The study included the three main organic anion-transporting polypeptide (OATP) 1B1, OATP1B3, and OATP2B1 but also the organic anion transporter (OAT) 2 and OAT7 and the sodium taurocholate protein (NTCP), all of which had decreased expression in NASH (Vildhede et al., 2020).

Several studies have demonstrated altered pharmacokinetics in patients with NASH using drugs whose elimination is dependent on the pathways described previously. A study performed with morphine reported that both hepatically-derived morphine glucuronides (morphine-3- and morphine-6-glucuronides) had increased C_{max} and area under the curves in the serum of patients with NASH and that the degree of this increase was correlated to the severity of the disease (Ferslew et al., 2015). A similar study was conducted with acetaminophen (APAP) in a pediatric population and found that patients with NASH had increased serum and urinary levels of APAP-glucuronide associated with decreased serum levels of APAP-sulfate (Canet et al., 2015). An impact on midazolam pharmacokinetics has also been detected in a cohort of patients with NASH presenting 2.4-fold higher plasma levels compared with controls (Woolsey et al., 2015).

One of the advantages of a pharmacokinetic biomarker is the potential for a single drug to be dependent upon multiple NASH-altered absorption, distribution, metabolism, and elimination processes that create a potentiated change in disposition. Much like how adding characters to the length of a password increases the security of identification, drugs using enzymes and transporters specifically impacted by NASH may increasingly differ in disposition and elimination. Additionally, pharmacokinetic disposition includes a component of directionality, wherein disposition of metabolites can be eliminated into bile or retained in plasma with consequent changes that can appear in liver impairment. Drugs that rely on metabolizing enzymes and uptake and efflux transporters that are each individually altered at the stage of NASH could have dramatic differences in patients with NASH when compared with patients with healthy livers, and the potential difference could allow a selective diagnosis. The specificity of this approach needs to be tested since many other factors may alter drug disposition, especially the absorption phase if the drug is given orally. However, the selection of a drug undergoing several overlapping mechanisms altered by NASH increases the specificity of this approach. The validation also

requires repeated tests to assess the feasibility and practicality and other parameters, such as the sensitivity and robustness of the method.

An advantage of this approach against the previous methods already existing is that the altered drug disposition might be used as a direct measure of hepatic function to indicate risks for ADRs from drugs that are dependent on enzymes and transporters altered in NASH. Hence, an exogenous probe drug strategy could have tremendous benefit in the drug development process as a companion diagnostic test for drugs with the potential for ADRs due to hepatic impairment. For such a test, the drug selected as the companion diagnostic should be validated by establishing a correlation between the pharmacokinetic changes observed for both the companion diagnostic and the drug being developed.

For exogenous diagnostics, additional safety standards must be considered. It is intuitive that the potential for any toxicity caused by the diagnostic probe drug must be significantly less than the disease to be diagnosed. As such, the ideal drug would need to be previously approved by the Food and Drug Administration for use in humans, have a long track record with minimal safety concerns, and have little to no pharmacologic effect at the dose used for diagnosis. Since the object of the exogenous probe drug is to identify pharmacokinetic changes rather than pharmacodynamic changes, it is possible to use a subtherapeutic dose of the probe drug that is as low as possible to be reasonably quantified in plasma and urine. This drug validated as a predictor of NASH would be administered in a single dose, and the test could be performed with a simple blood and urine sample to assess the concentration of the drug and its metabolites. The results measured would be compared with thresholds for healthy and disease individuals validated beforehand.

Conclusion

The development of an accurate, noninvasive diagnostic tool would streamline the diagnosis of patients with NASH and provide a direct indication of hepatic impairment that could identify individuals at risk for future ADRs. Currently, no approved pharmacotherapy is available for patients with NASH, but several drugs are in the pipeline. It is critical that the population in need of these therapies is readily identifiable. Using the novel strategy of pharmacokinetic changes of exogenous probe drugs has the capacity to provide a precise diagnostic tool. This strategy represents an unexplored but mechanistically promising approach to directly assess hepatic impairment via exogenous predictors and opens new clinical opportunities.

Authorship Contributions

Wrote or contributed to the writing of the manuscript: Marie, Tripp, Cherrington.

References

- Adams LA, Anstee QM, Tilg H, and Targher G (2017) Non-alcoholic fatty liver disease and its relationship with cardiovascular disease and other extrahepatic diseases. *Gut* **66**:1138–1153.
- Ahmed A, Wong RJ, and Harrison SA (2015) Nonalcoholic fatty liver disease review: diagnosis, treatment, and outcomes. *Clin Gastroenterol Hepatol* **13**:2062–2070.
- Allard J, Le Guillou D, Begriche K, and Fromenty B (2019) Chapter three - drug-induced liver injury in obesity and nonalcoholic fatty liver disease, in *Advances in Pharmacology* (Ramachandran A and Jaeschke H, eds) pp 75–107, Elsevier.
- Angulo P, Hui JM, Marchesini G, Bugianesi E, George J, Farrell GC, Enders F, Saksena S, Burt AD, Bida JP, et al. (2007) The NAFLD fibrosis score: a noninvasive system that identifies liver fibrosis in patients with NAFLD. *Hepatology* **45**:846–854.
- Arab JP, Barrera F, and Arrese M (2018) The evolving role of liver biopsy in non-alcoholic fatty liver disease. *Ann Hepatol* **17**:899–902 Elsevier.
- Bedogni G, Kahn HS, Bellentani S, and Tiribelli C (2010) A simple index of lipid overaccumulation is a good marker of liver steatosis. *BMC Gastroenterol* **10**:98.
- Bedossa P; FLIP Pathology Consortium (2014) Utility and appropriateness of the fatty liver inhibition of progression (FLIP) algorithm and steatosis, activity, and fibrosis (SAF) score in the evaluation of biopsies of nonalcoholic fatty liver disease. *Hepatology* **60**:565–575.

- Brenner D and Hall E (2007) Computed tomography — an increasing source of radiation exposure. <http://dx.doi.org.proxy.insermbiblio.inist.fr/101056/NEJMra072149>, doi: 10.1056/NEJMra072149, Massachusetts Medical Society.
- Browning JD, Szczepaniak LS, Dobbins R, Nuremberg P, Horton JD, Cohen JC, Grundy SM, and Hobbs HH (2004) Prevalence of hepatic steatosis in an urban population in the United States: impact of ethnicity. *Hepatology* **40**:1387–1395.
- Brunt EM, Kleiner DE, Wilson LA, Belt P, and Neuschwander-Tetri BA; NASH Clinical Research Network (CRN) (2011) Nonalcoholic fatty liver disease (NAFLD) activity score and the histopathologic diagnosis in NAFLD: distinct clinicopathologic meanings. *Hepatology* **53**:810–820.
- Canet MJ, Merrell MD, Hardwick RN, Bataille AM, Campion SN, Ferreira DW, Xanthakos SA, Manautou JE, A-Kader HH, Erickson RP, et al. (2015) Altered regulation of hepatic efflux transporters disrupts acetaminophen disposition in pediatric nonalcoholic steatohepatitis. *Drug Metab Dispos* **43**:829–835 American Society for Pharmacology and Experimental Therapeutics.
- Castera L, Friedrich-Rust M, and Loomba R (2019) Noninvasive assessment of liver disease in patients with nonalcoholic fatty liver disease. *Gastroenterology* **156**:1264–1281.e4.
- Chalasani N, Bonkovsky HL, Fontana R, Lee W, Stolz A, Talwalkar J, Reddy KR, Watkins PB, Navarro V, Barnhart H, et al.; United States Drug Induced Liver Injury Network (2015) Features and outcomes of 899 patients with drug-induced liver injury: the DILIN Prospective Study. *Gastroenterology* **148**:1340–52.e7.
- Chalasanani N, Younossi Z, Lavine JE, Charlton M, Cusi K, Rinella M, Harrison SA, Brunt EM, and Sanyal AJ (2018) The diagnosis and management of nonalcoholic fatty liver disease: practice guidance from the American Association for the Study of Liver Diseases. *Hepatology* **67**:328–357.
- Chen L, Brenner DA, and Kisseleva T (2018) Combatting fibrosis: exosome-based therapies in the regression of liver fibrosis. *Hepatology Commun* **3**:180–192.
- Conde-Vancells J, Rodriguez-Suarez E, Gonzalez E, Berisa A, Gil D, Embade N, Valle M, Luka Z, Elortza F, Wagner C, et al. (2010) Candidate biomarkers in exosome-like vesicles purified from rat and mouse urine samples. *Proteomics Clin Appl* **4**:416–425.
- Cui J, Ang B, Haufe W, Hernandez C, Verna EC, Sirlin CB, and Loomba R (2015) Comparative diagnostic accuracy of magnetic resonance elastography vs. eight clinical prediction rules for non-invasive diagnosis of advanced fibrosis in biopsy-proven non-alcoholic fatty liver disease: a prospective study. *Aliment Pharmacol Ther* **41**:1271–1280.
- Deffieux T, Gennisson JL, Bousquet L, Corouge M, Cosconea S, Amroun D, Tripson S, Terris B, Mallet V, Sogni P, et al. (2015) Investigating liver stiffness and viscosity for fibrosis, steatosis and activity staging using shear wave elastography. *J Hepatol* **62**:317–324.
- Dioguardi Burgio M, Imbault M, Ronot M, Faccinnetto A, Van Beers BE, Rautou PE, Castera L, Gennisson JL, Tanter M, and Vilgrain V (2019) Ultrasonic adaptive sound speed estimation for the diagnosis and quantification of hepatic steatosis: a pilot study. *Ultraschall Med - Ultraschall Med* **40**:722–733.
- Dixon JB, Bhathal PS, and O'Brien PE (2001) Nonalcoholic fatty liver disease: predictors of non-alcoholic steatohepatitis and liver fibrosis in the severely obese. *Gastroenterology* **121**:91–100.
- Doycheva I, Cui J, Nguyen P, Costa E, Hooker J, Hofflich H, Bettencourt R, Brouha S, Sirlin C, and Loomba R (2016) Non-invasive screening for NAFLD and advanced fibrosis in diabetes in primary care setting by MRI and MRE. *Aliment Pharmacol Ther* **43**:83–95.
- Dulai PS, Sirlin CB, and Loomba R (2016) MRI and MRE for non-invasive quantitative assessment of hepatic steatosis and fibrosis in NAFLD and NASH: clinical trials to clinical practice. *J Hepatol* **65**:1006–1016.
- European Association for the Study of the Liver (EASL); European Association for the Study of Diabetes (EASD); European Association for the Study of Obesity (EASO) (2016) EASL-EASD-EASO Clinical Practice Guidelines for the management of non-alcoholic fatty liver disease. *J Hepatol* **64**:1388–1402.
- Fedchuk L, Nascimbeni F, Pais R, Charlotte F, Housset C, and Ratzu V; LIDO Study Group (2014) Performance and limitations of steatosis biomarkers in patients with nonalcoholic fatty liver disease. *Aliment Pharmacol Ther* **40**:1209–1222.
- Ferslew BC, Johnston CK, Tsakalozou E, Bridges AS, Paine MF, Jia W, Stewart PW, Barritt 4th AS, and Brouwer KL (2015) Altered morphine glucuronide and bile acid disposition in patients with nonalcoholic steatohepatitis. *Clin Pharmacol Ther* **97**:419–427.
- Fisher CD, Lickteig AJ, Augustine LM, Ranger-Moore J, Jackson JP, Ferguson SS, and Cherrington NJ (2009) Hepatic cytochrome P450 enzyme alterations in humans with progressive stages of non-alcoholic fatty liver disease. *Drug Metab Dispos* **37**:2087–2094.
- Goldberg D, Ditah IC, Saeian K, Lalezari M, Aronson A, Gorospe EC, and Charlton M (2017) Changes in the prevalence of hepatitis C virus infection, non-alcoholic steatohepatitis, and alcoholic liver disease among patients with cirrhosis or liver failure on the waitlist for liver transplantation. *Gastroenterology* **152**:1090–1099.e1.
- Hardwick RN, Ferreira DW, More VR, Lake AD, Lu Z, Manautou JE, Slitt AL, and Cherrington NJ (2013) Altered UDP-glucuronosyltransferase and sulfotransferase expression and function during progressive stages of human nonalcoholic fatty liver disease. *Drug Metab Dispos* **41**:554–561.
- Hardwick RN, Fisher CD, Canet MJ, Lake AD, and Cherrington NJ (2010) Diversity in antioxidant response enzymes in progressive stages of human nonalcoholic fatty liver disease. *Drug Metab Dispos* **38**:2293–2301.
- Hardwick RN, Fisher CD, Canet MJ, Scheffer GL, and Cherrington NJ (2011) Variations in ATP-binding cassette transporter regulation during the progression of human nonalcoholic fatty liver disease. *Drug Metab Dispos* **39**:2395–2402.
- Imbault M, Dioguardi Burgio M, Faccinnetto A, Ronot M, Bendjador H, Deffieux T, Triquet EO, Rautou PE, Castera L, Gennisson JL, et al. (2018) Ultrasonic fat fraction quantification using in vivo adaptive sound speed estimation. *Phys Med Biol* **63**:215013 IOP Publishing.
- Imbault M, Faccinnetto A, Osmani BF, Tissier A, Deffieux T, Gennisson JL, Vilgrain V, and Tanter M (2017) Robust sound speed estimation for ultrasound-based hepatic steatosis assessment. *Phys Med Biol* **62**:3582–3598 IOP Publishing.
- Kleiner DE, Brunt EM, Van Natta M, Behling C, Contos MJ, Cummings OW, Ferrell LD, Liu YC, Torbenson MS, Unalp-Arida A, et al.; Nonalcoholic Steatohepatitis Clinical Research Network (2005) Design and validation of a histological scoring system for nonalcoholic fatty liver disease. *Hepatology* **41**:1313–1321.
- Komek M, Lynch M, Mehta SH, Lai M, Exley M, Afdhal NH, and Schuppan D (2012) Circulating microparticles as disease-specific biomarkers of severity of inflammation in patients with hepatitis C or nonalcoholic steatohepatitis. *Gastroenterology* **143**:448–458.
- Lammert C, Imler T, Teal E, and Chalasani N (2019) Patients with chronic liver disease suggestive of nonalcoholic fatty liver disease may be at higher risk for drug-induced liver injury. *Clin Gastroenterol Hepatol* **17**:2814–2815.
- Lee W, Glaeser H, Smith LH, Roberts RL, Moeckel GW, Gervasini G, Leake BF, and Kim RB (2005) Polymorphisms in human organic anion-transporting polypeptide 1A2 (OATP1A2): implications for altered drug disposition and central nervous system drug entry. *J Biol Chem* **280**:9610–9617.
- Lee JH, Kim D, Kim HJ, Lee CH, Yang JJ, Kim W, Kim YI, Yoon JH, Cho SH, Sung MW, et al. (2010) Hepatic steatosis index: a simple screening tool reflecting nonalcoholic fatty liver disease. *Dig Liver Dis* **42**:503–508.
- Lee SS and Park SH (2014) Radiologic evaluation of nonalcoholic fatty liver disease. *World J Gastroenterol* **20**:7392–7402.
- Li H, Canet MJ, Clarke JD, Billheimer D, Xanthakos SA, Lavine JE, Erickson RP, and Cherrington NJ (2017) Pediatric cytochrome P450 activity alterations in nonalcoholic steatohepatitis. *Drug Metab Dispos* **45**:1317–1325.
- Li H, Toth E, and Cherrington NJ (2018a) Asking the right questions with animal models: methionine- and choline-deficient model in predicting adverse drug reactions in human NASH. *Toxicol Sci* **161**:23–33.
- Li Q, Dhyani M, Grajo JR, Sirlin C, and Samir AE (2018b) Current status of imaging in nonalcoholic fatty liver disease. *World J Hepatol* **10**:530–542.
- Madrazo BL (2017) Diagnosis of nonalcoholic steatohepatitis without liver biopsy. *Gastroenterol Hepatol (N Y)* **13**:378–380.
- Malhi H (2019) Emerging role of extracellular vesicles in liver diseases. *Am J Physiol Gastrointest Liver Physiol* **317**:G739–G749.
- Massart J, Begriche K, Moreau C, and Fromenty B (2017) Role of nonalcoholic fatty liver disease as risk factor for drug-induced hepatotoxicity. *J Clin Transl Res* **3** (Suppl 1):212–232.
- Myers RP, Pollett A, Kirsch R, Pomier-Layrargues G, Beaton M, Levstik M, Duarte-Rojo A, Wong D, Crotty P, and Elkashab M (2012) Controlled attenuation parameter (CAP): a noninvasive method for the detection of hepatic steatosis based on transient elastography. *Liver Int* **32**:902–910.
- Newman LA, Sorich MJ, and Rowland A (2020) Role of extracellular vesicles in the pathophysiology, diagnosis and tracking of non-alcoholic fatty liver disease. *J Clin Med* **9**:2032.
- Noureddin M, Lam J, Peterson MR, Middleton M, Hamilton G, Le TA, Bettencourt R, Changchien C, Brenner DA, Sirlin C, et al. (2013) Utility of magnetic resonance imaging versus histology for quantifying changes in liver fat in nonalcoholic fatty liver disease trials. *Hepatology* **58**:1930–1940.
- Obika M and Noguchi H (2012) Diagnosis and evaluation of nonalcoholic fatty liver disease. *Exp Diabetes Res* **2012**:145754.
- Okushin K, Tsutsumi T, Enooku K, Fujinaga H, Kado A, Shibahara J, Fukayama M, Moriya K, Yotsuyanagi H, and Koike K (2016) The intrahepatic expression levels of bile acid transporters are inversely correlated with the histological progression of nonalcoholic fatty liver disease. *J Gastroenterol* **51**:808–818.
- Palekar NA, Naus R, Larson SP, Ward J, and Harrison SA (2006) Clinical model for distinguishing nonalcoholic steatohepatitis from simple steatosis in patients with nonalcoholic fatty liver disease. *Liver Int* **26**:151–156.
- Park SH, Kim PN, Kim KW, Lee SW, Yoon SE, Park SW, Ha HK, Lee MG, Hwang S, Lee SG, et al. (2006) Macrovesicular hepatic steatosis in living liver donors: use of CT for quantitative and qualitative assessment. *Radiology* **239**:105–112 Radiological Society of North America.
- Piazzolla VA and Mangia A (2020) Noninvasive diagnosis of NAFLD and NASH. *Cells* **9**:1005.
- Pirola CJ, Fernández Gianotti T, Castano GO, Mallardi P, San Martino J, Mora Gonzalez Lopez Ledesma M, Flichman D, Mirshahi F, Sanyal AJ, and Sookoian S (2015) Circulating microRNA signature in non-alcoholic fatty liver disease: from serum non-coding RNAs to liver histology and disease pathogenesis. *Gut* **64**:800–812.
- Poynard T, Peta V, Munteanu M, Charlotte F, Ngo Y, Ngo A, Perazzo H, Deckmyn O, Pais R, Mathurin P, et al.; FLIP consortium, the FibroFrance-CPAM group, the FibroFrance-Obese group, and the Selonsertib group (2019) The diagnostic performance of a simplified blood test (SteatoTest-2) for the prediction of liver steatosis. *Eur J Gastroenterol Hepatol* **31**:393–402.
- Poynard T, Ratzu V, Charlotte F, Messous D, Munteanu M, Imbert-Bismut F, Massard J, Bonyhay L, Tahiri M, Thabut D, et al.; LIDO Study Group; CYTOL study group (2006) Diagnostic value of biochemical markers (NashTest) for the prediction of non alcoholic steato hepatitis in patients with non-alcoholic fatty liver disease. *BMC Gastroenterol* **6**:34.
- Poynard T, Ratzu V, Naveau S, Thabut D, Charlotte F, Messous D, Capron D, Abella A, Massard J, Ngo Y, et al. (2005) The diagnostic value of biomarkers (SteatoTest) for the prediction of liver steatosis. *Comp Hepatol* **4**:10.
- Pu K, Wang Y, Bai S, Wei H, Zhou Y, Fan J, and Qiao L (2019) Diagnostic accuracy of controlled attenuation parameter (CAP) as a non-invasive test for steatosis in suspected non-alcoholic fatty liver disease: a systematic review and meta-analysis. *BMC Gastroenterol* **19**:51.
- Qi S, Xu D, Li Q, Xie N, Xia J, Huo Q, Li P, Chen Q, and Huang S (2017) Metabonomics screening of serum identifies pyroglutamate as a diagnostic biomarker for nonalcoholic steatohepatitis. *Clin Chim Acta* **473**:89–95.
- Rockey DC, Caldwell SH, Goodman ZD, Nelson RC, and Smith AD; American Association for the Study of Liver Diseases (2009) Liver biopsy. *Hepatology* **49**:1017–1044.
- Ruffillo G, Fassio E, Alvarez E, Landeira G, Longo C, Domínguez N, and Gualano G (2011) Comparison of NAFLD fibrosis score and BARD score in predicting fibrosis in nonalcoholic fatty liver disease. *J Hepatol* **54**:160–163.
- Sandrin L, Tanter M, Gennisson J-L, Catheline S, and Fink M (2002) Shear elasticity probe for soft tissues with 1-D transient elastography. *IEEE Trans Ultrason Ferroelectr Freq Control* **49**:436–446.
- Shah AG, Lydecker A, Murray K, Tetri BN, Contos MJ, and Sanyal AJ; Nash Clinical Research Network (2009) Comparison of noninvasive markers of fibrosis in patients with nonalcoholic fatty liver disease. *Clin Gastroenterol Hepatol* **7**:1104–1112.
- Shannon A, Alkhouri N, Carter-Kent C, Monti L, Devito R, Lopez R, Feldstein A, and Nobili V (2011) Ultrasonographic quantitative estimation of hepatic steatosis in children with nonalcoholic fatty liver disease (NAFLD). *J Pediatr Gastroenterol Nutr* **53**:190–195.
- Singh D, Das CJ, and Baruah MP (2013) Imaging of non alcoholic fatty liver disease: A road less travelled. *Indian J Endocrinol Metab* **17**:990–995.
- Singh S, Allen AM, Wang Z, Prokop LJ, Murad MH, and Loomba R (2015) Fibrosis progression in nonalcoholic fatty liver vs nonalcoholic steatohepatitis: a systematic review and meta-analysis of paired-biopsy studies. *Clin Gastroenterol Hepatol* **13**:643–54.e1, 9, quiz e39–e40.

- Springer F, Machann J, Claussen CD, Schick F, and Schwenzer NF (2010) Liver fat content determined by magnetic resonance imaging and spectroscopy. *World J Gastroenterol* **16**: 1560–1566.
- Sumida Y, Nakajima A, and Itoh Y (2014) Limitations of liver biopsy and non-invasive diagnostic tests for the diagnosis of nonalcoholic fatty liver disease/nonalcoholic steatohepatitis. *World J Gastroenterol* **20**:475–485.
- Szabo G and Csak T (2016) Role of MicroRNAs in NAFLD/NASH. *Dig Dis Sci* **61**:1314–1324.
- Tanaka N, Matsubara T, Krausz KW, Patterson AD, and Gonzalez FJ (2012) Disruption of phospholipid and bile acid homeostasis in mice with nonalcoholic steatohepatitis. *Hepatology* **56**:118–129.
- Tang A, Tan J, Sun M, Hamilton G, Bydder M, Wolfson T, Gamst AC, Middleton M, Brunt EM, Loomba R, et al. (2013) Nonalcoholic fatty liver disease: MR imaging of liver proton density fat fraction to assess hepatic steatosis. *Radiology* **267**:422–431.
- Tanwar S, Tremblay PM, Guha IN, Parkes J, Kaye P, Burt AD, Ryder SD, Aithal GP, Day CP, and Rosenberg WM (2013) Validation of terminal peptide of procollagen III for the detection and assessment of nonalcoholic steatohepatitis in patients with nonalcoholic fatty liver disease. *Hepatology* **57**:103–111.
- Vallet-Pichard A, Mallet V, Nalpas B, Verkarre V, Nalpas A, Dhalluin-Venier V, Fontaine H, and Pol S (2007) FIB-4: an inexpensive and accurate marker of fibrosis in HCV infection. Comparison with liver biopsy and fibrotest. *Hepatology* **46**:32–36.
- Venkatesh SK, Yin M, and Ehman RL (2013) Magnetic resonance elastography of liver: technique, analysis, and clinical applications. *J Magn Reson Imaging* **37**:544–555.
- Vildhede A, Kimoto E, Pelis RM, Rodrigues AD, and Varma MVS (2020) Quantitative proteomics and mechanistic modeling of transporter-mediated disposition in nonalcoholic fatty liver disease. *Clin Pharmacol Ther* **107**:1128–1137.
- Wieckowska A, Zein NN, Yerian LM, Lopez AR, McCullough AJ, and Feldstein AE (2006) In vivo assessment of liver cell apoptosis as a novel biomarker of disease severity in nonalcoholic fatty liver disease. *Hepatology* **44**:27–33.
- Wong VW, Vergniol J, Wong GL, Foucher J, Chan HL, Le Bail B, Choi PC, Koww M, Chan AW, Merrouche W, et al. (2010) Diagnosis of fibrosis and cirrhosis using liver stiffness measurement in nonalcoholic fatty liver disease. *Hepatology* **51**:454–462.
- Woolsey SJ, Mansell SE, Kim RB, Tirona RG, and Beaton MD (2015) CYP3A activity and expression in nonalcoholic fatty liver disease. *Drug Metab Dispos* **43**:1484–1490 American Society for Pharmacology and Experimental Therapeutics.
- Yin M, Talwalkar JA, Glaser KJ, Manduca A, Grimm RC, Rossman PJ, Fidler JL, and Ehman RL (2007) Assessment of hepatic fibrosis with magnetic resonance elastography. *Clin Gastroenterol Hepatol* **5**:1207–1213.e2.
- Yokoo T, Shieh-morteza M, Hamilton G, Wolfson T, Schroeder ME, Middleton MS, Bydder M, Gamst AC, Kono Y, Kuo A, et al. (2011) Estimation of hepatic proton-density fat fraction by using MR imaging at 3.0 T. *Radiology* **258**:749–759.
- Younossi ZM, Koenig AB, Abdelatif D, Fazel Y, Henry L, and Wymer M (2016) Global epidemiology of nonalcoholic fatty liver disease—meta-analytic assessment of prevalence, incidence, and outcomes. *Hepatology* **64**:73–84.
- Younossi ZM (2018) The epidemiology of nonalcoholic steatohepatitis. *Clin Liver Dis (Hoboken)* **11**:92–94.
- Younossi ZM, Loomba R, Anstee QM, Rinella ME, Bugianesi E, Marchesini G, Neuschwander-Tetri BA, Serfaty L, Negro F, Caldwell SH, et al. (2018a) Diagnostic modalities for nonalcoholic fatty liver disease, nonalcoholic steatohepatitis, and associated fibrosis. *Hepatology* **68**:349–360.
- Younossi ZM, Loomba R, Rinella ME, Bugianesi E, Marchesini G, Neuschwander-Tetri BA, Serfaty L, Negro F, Caldwell SH, Ratziu V, et al. (2018b) Current and future therapeutic regimens for nonalcoholic fatty liver disease and nonalcoholic steatohepatitis. *Hepatology* **68**:361–371.
- Younossi ZM, Stepanova M, Ong J, Trimble G, AlQahtani S, Younossi I, Ahmed A, Racila A, and Henry L (2021) Nonalcoholic steatohepatitis is the most rapidly increasing indication for liver transplantation in the United States. *Clin Gastroenterol Hepatol* **19**:580–589.e5.
- Zhou JH, Cai JJ, She ZG, and Li HL (2019) Noninvasive evaluation of nonalcoholic fatty liver disease: current evidence and practice. *World J Gastroenterol* **25**:1307–1326.
- Zhou Y, Orešić M, Leivonen M, Gopalacharyulu P, Hyysalo J, Arola J, Verrijken A, Francque S, Van Gaal L, Hyötyläinen T, et al. (2016) Noninvasive detection of nonalcoholic steatohepatitis using clinical markers and circulating levels of lipids and metabolites. *Clin Gastroenterol Hepatol* **14**:1463–1472.e6.

Address correspondence to: Nathan J. Cherrington, 1295 N. Martin Ave., Tucson, AZ, 85721. E-mail: cherrington@pharmacy.arizona.edu
